

Choroidal Melanomas

Update on Diagnosis & Treatment

Peter H. Tang, M.D., Ph.D.



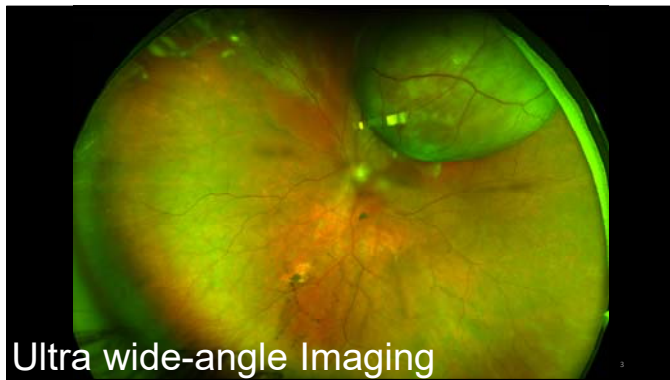
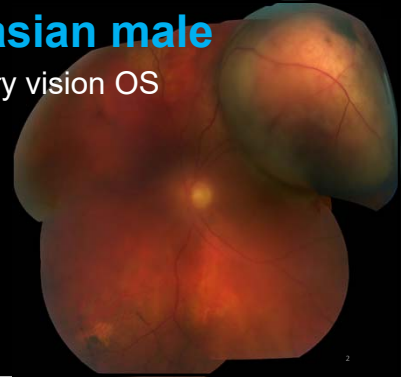28 yo Caucasian male

CC: 5 yr hx of blurry vision OS

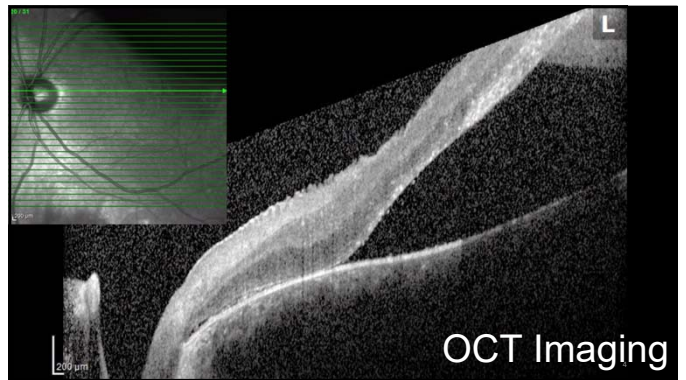
BCVA: CF

IOP: 15 mmHg

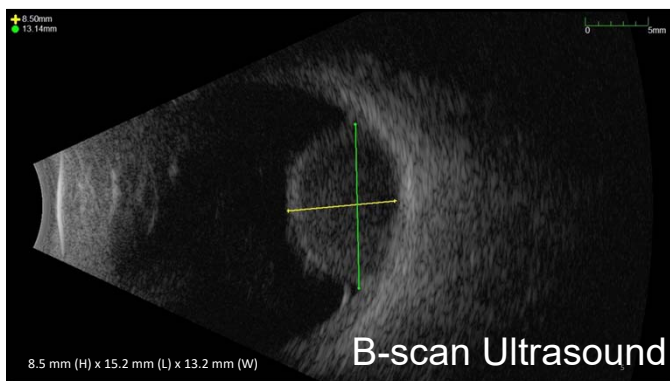
Ant seg: normal



Ultra wide-angle Imaging



OCT Imaging




B-scan Ultrasound


Treatment




Teamwork



Eye Care
Community



VRS
Vitreoretinal
Surgery, P.A.



Peter Tang, M.D., Ph.D.
Retinal Surgeon

Collaborative Approach



Peter Tang, M.D., Ph.D.
Retinal Surgeon



Evidio Domingo-Musibay, M.D.
Medical Oncologist

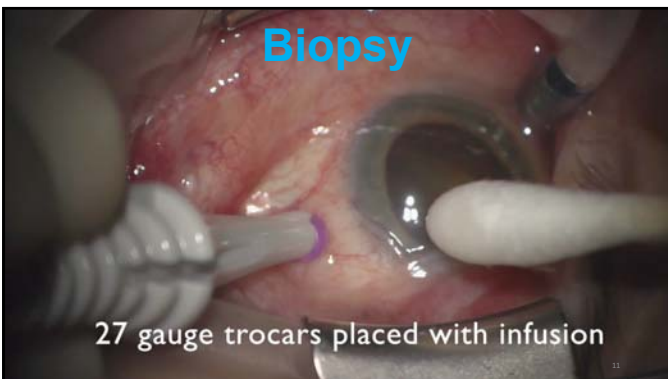
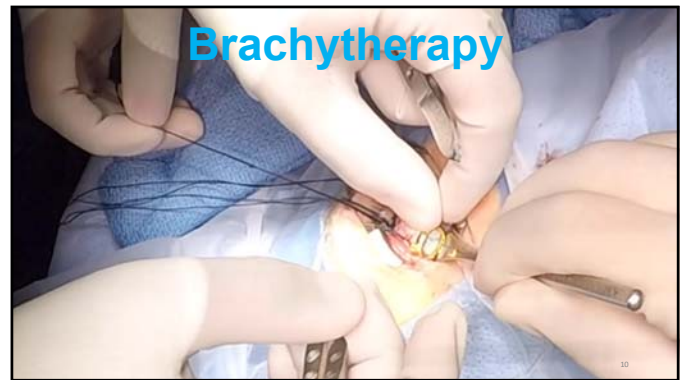

Clara Ferreira, Ph.D.
Physicist



Kathryn Dusenbery, M.D.
Radiation Oncologist



Genetics

- Chromosome 3 loss
- *Bap1* gene mutations
- Chromosome 8 gain
- Chromosome 6p gain
- *Gnaq* and *Gna11* mutations
- *Eif1ax* and *Sf3b1* mutations
- *Srsf2* mutations
- *Plcb4* mutations
- *Cysltr2* mutations

Very confusing!

Genetic Expression Profiling

- 15 gene assay using machine learning
- Classifications with clinical implications

GEP Profile	% metastasis-free at 3 yrs	% metastasis-free at 5 yrs
Class 1A	98%	98%
Class 1B	93%	79%
Class 2	50%	28%



13

Preferentially expressed antigen in melanoma (PRAME)

- Independent biomarker for metastasis
- Increased metastatic risk when mRNA is detected

GEP + PRAME?

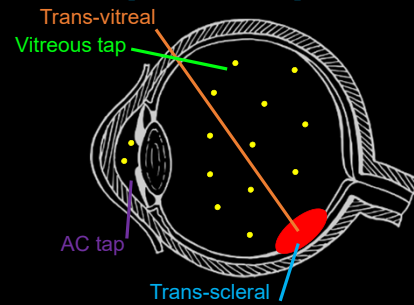
14

Liquid Biopsies

- Genetic evaluation of retinoblastoma from samples taken from blood and aqueous humor
- Safer and less invasive biopsies
- Could this be applied to choroidal melanomas?

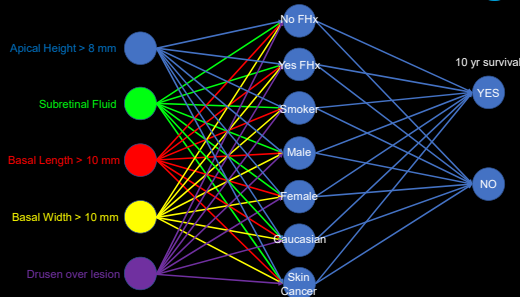
15

Liquid Biopsies

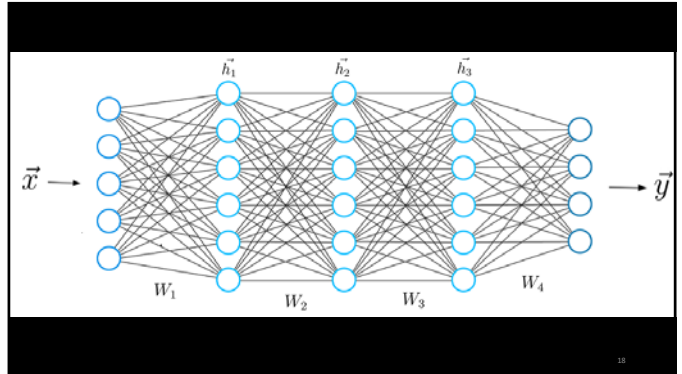


16

Machine Learning



17



18

